

The Impact of Different Seizure Control in Brain Atrophy in Temporal Lobe Epilepsy: a Voxel Based Morphometry Analysis

Lucas L. Montanher*, Letícia F. Ribeiro, José C. V. Moreira, Guilherme Artoni, Marina K. M. Alvim, Fernando Cendes, Clarissa L. Yasuda

Abstract

Temporal Lobe Epilepsy (TLE) is the most common epileptic syndrome in adult, with a high documented drug resistance rate. There are many forms of presentation of TLE, that varies significantly in severity and seizure control. Many studies have shown brain atrophy in patients with temporal lobe epilepsy, but few have compared the impact of refractory seizures on grey and white matter atrophy. In this study we applied voxel-based morphometry (VBM), a MRI morphometric technique largely used in epilepsy and others neurological disorders, to evaluate the relation between severity of the disease and brain atrophy in TLE patients.

Key words:

temporal lobe epilepsy, voxel-based morphometry, seizures control

Introduction

Temporal Lobe Epilepsy (TLE), a subtype of focal type epilepsy, is the most common epileptic syndrome in adults, affecting around 1% of the world population¹. It is estimated that approximately 1/3 of patients with epilepsy are resistant to Anti-Epileptic Drugs (AEDs) and, in this context, TLE represents the primary source of refractory epilepsy, with the highest rate of drug-resistant patients². However, little has been studied about the impact of seizure control on the observed abnormalities. In the present study, we evaluated the patterns of white (WM) and grey matter (GM) atrophy in patients with TLE with refractory, fluctuating, early and late seizures control. Our objective was to analyze the global brain involvement in patients with TLE correlating different degrees of seizure outcome to the observed structural alterations.

Results and Discussion

We carried out analyzes of MRI from the Neuroimaging Laboratory's database of 226 patients followed up at the epilepsy service at HC-Unicamp. Patients were divided into four groups: 1) refractory seizures, 2) fluctuating seizures, 3) early seizures control, 4) late seizures control. The analyzes were performed with the software Computational Anatomy Toolbox (CAT12)/SPM12/MATLAB2014 (using the voxel-based morphometry (VBM) technique). All patients were compared with 210 healthy controls, and statistical analyzes were performed using the Statistical Parametric Mapping (SPM) software.

We observed areas of white and grey matter atrophy in the brains of patients affected by TLE in relation to healthy controls. In addition, there are significant differences in terms of GM atrophy in the different clinical groups of the study. In patients with refractory seizures (Group 1) and with fluctuating seizures (Group 2), the atrophic effect is more evident and widespread when compared with

patients with early (Group 3) and late (Group 4) seizures control. On the other hand, from the results shown, patients with early control of seizures appear to have more exuberant areas of atrophy than the group of patients with late seizure control. There was a widespread pattern of WM atrophy, mainly in the refractory group.

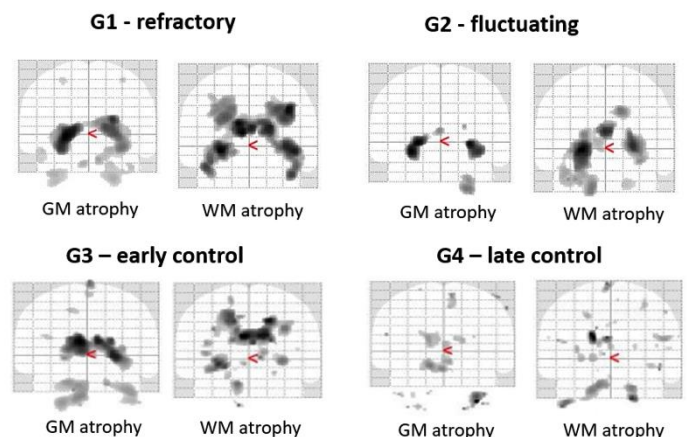


Image 1. Comparison of White and Grey Matter atrophy in all groups in relation to healthy controls.

Conclusions

In our research, we noticed bilateral atrophy in brain's white and grey matter in all groups of patients when compared with healthy volunteers. Our results suggest a negative and more intense impact of refractory seizures in WM and GM in temporal lobe epilepsy. The control of seizures should help not only in the reduction of morbidity and mortality of the disease, but also in preservation of the cognition of these patients.

¹ - Long, H.Y., et al. Blood DNA methylation pattern is altered in mesial temporal lobe epilepsy. *Sci Rep.* 2017, 9;7:43810;

² - Coyle, A., et al. From resection to ablation: A review of resective surgical options for temporal lobe epilepsy and rationale for an ablation-based approach. *Neurol India.* 2017, 65(Supplement):S71-S77;