



Dose dependent treatment with a retinoid does not alter Wistar rat prostate

Amanda B. Pexe*, Bruna F. Thomazini and Mary Anne H. Dolder

Abstract

Isotretinoin is a synthetic substance similar to vitamin A, widely used in dermatological medicines that help in the treatment of severe acne. This drug may be considered a possible harmful factor to the male reproductive system, causing structural changes in these organs, since the drug is directly related to cell proliferation and differentiation. Thus, this study aims to assess the prostate, to be added to conclusions obtained from the assessment of structures potentially affected by isotretinoin.

Key words:

isotretinoin, retinoid, prostate

Introduction

Some retinoids, such as 13-cis-retinoic acid, contribute to relieving severe acne⁴. This substance is derived from Vitamin A¹ and promotes cellular differentiation². Since the male reproductive system is sensitive to environmental conditions and drug use³, it is important to evaluate isotretinoin as a possibly harmful factor, which may result in permanent or transient infertility of patients. Thus, this study aims to elucidate the effect of this retinoid, evaluating its toxicity as shown by prostate morphology in Wistar rats, contributing to conclusions as to drug safety in the reproductive parameters.

Results and Discussion

The results obtained in this research refer to the prostate of Wistar rats (Fig 1 and 2), divided in four groups (n=6): Control C, water; D0, soybean oil; D1, isotretinoin 1mg/kg; D10, isotretinoin 10mg/kg. The drug was diluted in soybean oil and offered daily by gavage for 60 days. In sections with PAS (Periodic Acid Schiff) histochemical technique, 10 random areas obtained with 200x magnification were considered for evaluation. A grid of 243 intersections per area was used to obtain the area proportion occupied by tubular epithelium, the lumen and the interstitium of the prostate. These data were obtained with Image-Pro Plus®. The statistical analysis was performed with Anova one way and the Tukey post test (p<0.05) using GraphPad® version 5.01. With this treatment no alterations of the prostate were observed, since the values obtained were statistically the same (Fig1).

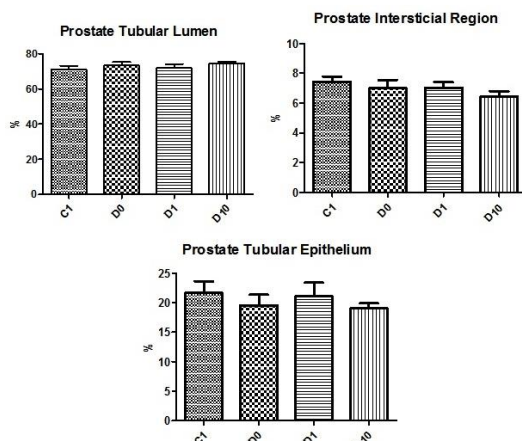


Fig 1: The treatment proposed with 1mg/kg and 10mg/kg of isotretinoin did not alter the proportion of tubular epithelium and lumen and interstitial region of Wistar rats prostate.

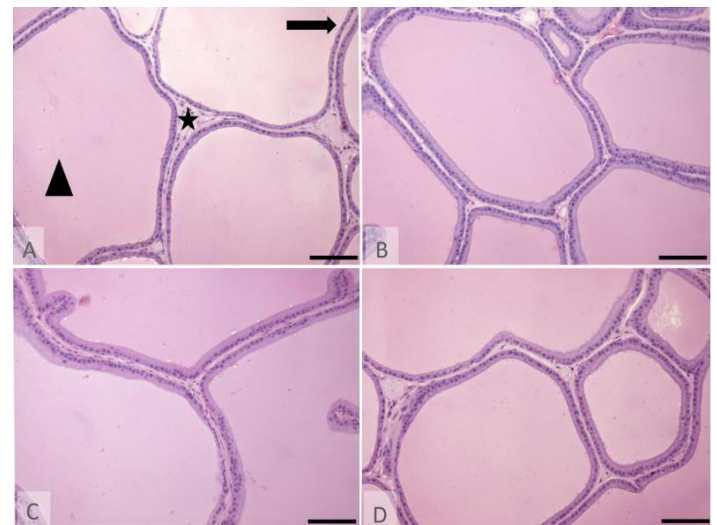


Fig 2. Photomicrographs of prostate with PAS histochemical technique. A: Group C (control, daily gavage with water); B: Group D0 (control, daily gavage of soybean oil); C: Group D1 (1mg / kg isotretinoin); D: Group D10 (10mg / kg isotretinoin). In image A, the triangle and the star represent, respectively, the lumen and interstitial region of the prostatic tubule and the arrow indicates the epithelium. Bar: 500µm.

Conclusions

The proposed treatment with isotretinoin applying 1mg/kg or 10mg/kg did not result in a significant difference of the parameters of the constituents analyzed, suggesting that these concentrations are safe for rats.

Acknowledgement

CNPq, CAPES, Fapesp (Proc. 2016/18201-0).

References:

- 1 KOCHHAR, D.M.; CHRISTIAN, M.S. Tretinoin: a review of the nonclinical development toxicology experience. *J. Am. Acad. Dermatol.*, St. Louis, MO, v. 36, n.3, Supl. 1, p. S47-S59, Mar. 1997.
- 2 SPORN, M. B, ROBERTS, A. B. What is a retinoid? In: *Retinoids differentiation and disease. Ciba Found Symp.*v.113, p. 1-5, 1985.
- 3 PANNOCHIA, M.A *et al*, Estratégia efetiva de fixação do testículo de ratos Wistar para avaliar os parâmetros morfológicos e morfométricos do epitélio seminífero. *ConScientiae Saúde*, 7(2): 227-233
- 4 GOULART, A. C. Efeitos do Roacutan® (Isotretinoína) sobre o aparelho reprodutor de Ratos Wistar adultos. 2013. 63 f. Dissertação (Mestrado em biologia animal) Universidade Federal de Viçosa, Minas Gerais, 2013.