

Basal Ganglia abnormalities in ALS: Texture and volumetric analysis

Lara G. V. Anjos, Milena Albuquerque, Marcondes C. F. Junior

Abstract

Amyotrophic Lateral Sclerosis (ALS) is the most common motor neuron disease in adults and characterized by extensive corticospinal damage. Pathological studies also suggest basal ganglia (BG) damage, but this is not yet settled. We thus used texture and volumetric analyses to investigate possible abnormalities in BG of 32 ALS patients in comparison with 32 healthy controls. We used MRI T1 volumetric sequences for segmentation. For statistic analyses, we used Mann-Whitney test, with a significance level of 0.025 (FDR-Corrected). Texture parameters were different in patients with ALS, mainly in the thalami and caudate nuclei. In contrast, volumetric analyses only found right thalamic atrophy. Our data confirm BG involvement, and suggest that texture abnormalities may precede true volumetric changes, emerging as a potential neuroimaging marker for ALS.

Key words: Amyotrophic Lateral Sclerosis, texture analysis, grey nuclei

Introduction

Amyotrophic Lateral Sclerosis is the most common motor neuron disease in adults. It is classically characterized by a fast neurodegeneration of upper and lower motor neurons, leading to death 3-5 years after diagnosis. Basal ganglia (BG) damage has been suggested in recent pathological studies, but there are very few *in vivo* data supporting this hypothesis. We have thus designed this study to assess BG structure using MRI datasets in a cohort of patients with ALS. We employed volumetric measurements and also texture analyses. The latter technique evaluates the distribution of gray levels within the pixels of an image and has proven useful in the evaluation of other neurodegenerative diseases.

Results and Discussion

We found significant differences between ALS patients and controls in the following texture parameters for right caudate nucleus and both thalami: Correlation and Inverse Difference Moment. These findings confirm BG damage in ALS and are in line with a recent study that found atrophy in the same structures in the disease. Nevertheless, our own volumetric study using the FreeSurfer software only showed right thalamic atrophy. This suggests that texture abnormalities may precede true atrophy. The clinical correlate of BG damage possibly includes cognitive and behavioral changes, but further studies are needed to investigate this.

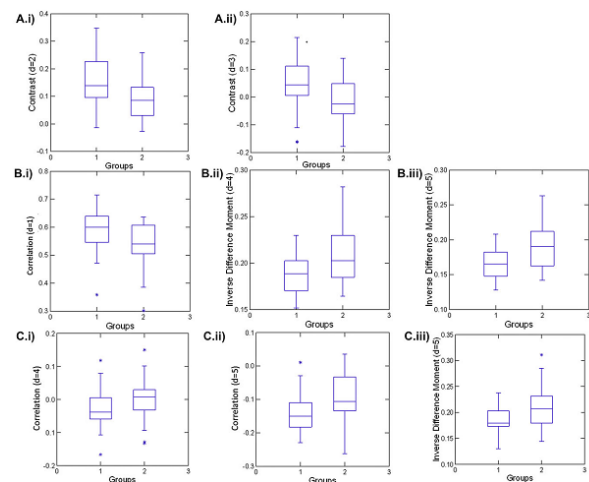


Image 1. Box plot showing structures and parameters that presented significant between-group differences

Conclusions

There is BG damage in ALS shown by texture and volumetric analyses of MRI datasets. Texture abnormalities appear earlier than volumetric reduction, thus suggesting the former to be more sensitive to detect changes in ALS. We intend to continue this study in a longitudinal setting to investigate the progression of cerebral damage and also the clinical correlates of such structural abnormalities

Acknowledgement

I would like to thank researchers from Neuroimaging and Neurophysics Laboratories